The Increasing Role of Epidermal Grafting Utilizing a Novel Harvesting System in Chronic Wounds

Thomas E. Serena, MD

WOUNDS 2015;27(2):26-30

From the SerenaGroup, Cambridge, MA

Address correspondence to:
Thomas E. Serena, MD
serena@serenagroups.com

Disclosure: The author discloses he is the founder and CEO of the SerenaGoup. He is also a consultant for KCI, an Acelity company.

Abstract: Skin grafting techniques range from harvesting full-thickness to split-thickness grafts to grafts containing only epidermis. All of these autologous tissues have their place on the reconstructive ladder. However, the use of full-thickness and split-thickness grafts as coverage over chronic wounds remains limited by a number of factors, including the need for anesthesia, a surgically trained physician, and an operating room in which to perform the procedure; pain and damage associated with the donor site; and severe patient comorbidities. Epidermal grafting offers an option for autografts and uses only a minimal amount of superficial epidermis from the donor site. Although successful use of epidermal grafting has been reported in pigmentation disorders, as well as burns and chronic wounds, previous harvesting methods have been described as cumbersome and time consuming. An automated epidermal harvesting system is now commercially available and involves a tool that applies both heat and suction concurrently to normal skin to induce epidermal micrograft formation. The new tool allows quick harvest and transfer of the epidermal micrografts at the bedside without anesthesia, with minimal donor site healing time and patient discomfort. The use of epidermal grafts in chronic wounds and the harvesting technique are reviewed here.

Key words: epidermal grafting, epidermal harvesting system, chronic wounds, autologous skin graft

Reconstructive options for patients requiring skin coverage include the use of autologous skin. Split-thickness skin grafts (STSGs) have been a mainstay in the reconstruction of acute wounds. In chronic ulcers, however, skin grafting has been supplanted by cellular and tissue-based products due to various limitations of STSGs, including the requirement of an operating room, anesthesia, and surgically trained specialist; a sizeable donor site that may have difficulty healing; and nondurable coverage in certain locations such as the plantar aspect of the foot.[1]

Epidermal grafting utilizes autologous skin, yet eliminates most of the drawbacks of STSGs when only epidermis is needed.[1,2] First introduced in 1964 by Kiistala and Mustakallio,[3] and used primarily by dermatologists for hypopigmented lesions,[4] epidermal grafting has not gained wide accep-

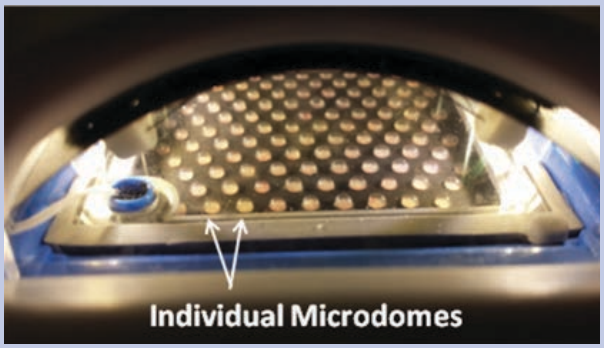

Figure 1. Epidermal microdomes are visibly forming after 30 minutes. *Reprinted with permission from KCI Licensing, Inc.*

tance for wound management largely because harvesting techniques have been tedious and time consuming.[5] Despite the reported difficulties in harvesting epidermal grafts, however, there are several reports of their successful use in burns and chronic wounds.[6-11] The majority of these cases employed a suction blister epidermal grafting (SBEG) technique during which epidermal blisters were raised using a suction apparatus, and epidermis was harvested using a free hand blade technique.

An automated system for epidermal harvesting (CelluTome Epidermal Harvesting System, KCI, an Acelity Company, San Antonio, TX) is commercially available. The system consists of a control unit, vacuum head, and harvester, and simultaneously warms the skin and applies negative pressure to harvest up to 128 epidermal microdomes (ie, the individual blisters that form when heat and suction are applied to the donor site by the epidermal harvesting system) (Figure 1). The harvesting time varies from 15 to 60 minutes with most epidermal microdomes ready for harvesting at 30 minutes, depending on the age of the patient and the thickness of the skin on the donor site. The epidermal grafts are then transferred to the recipient site and secured in place using compression wraps, bolster dressings, negative pressure wound therapy, or any other dressings as determined by the treating clinician.

This automated epidermal harvesting procedure has been shown to be far less time consuming and considerably more reproducible than previous SBEG methods. A preclinical study performed on 12 healthy volunteers demonstrated that an average of 99.5%—10 volunteers had 100% viability; 1 volunteer had 97.4% viability; and 1 volunteer had 96.6%—of the epidermal microdomes remained viable after harvesting with this technique (Figure 2).[12] In addition, histological examination showed that the epidermal microdomes formed at the dermaepidermal junction and contained proliferative cells that secrete wound healing growth factors (eg, vascular endothelial growth factor, transforming growth factor alpha, platelet-derived growth factor, hepatocyte growth factor, and granulocyte colony-stimulating factor) (Figure 3).[13] The absence of pain sensory organs in the epidermis re-

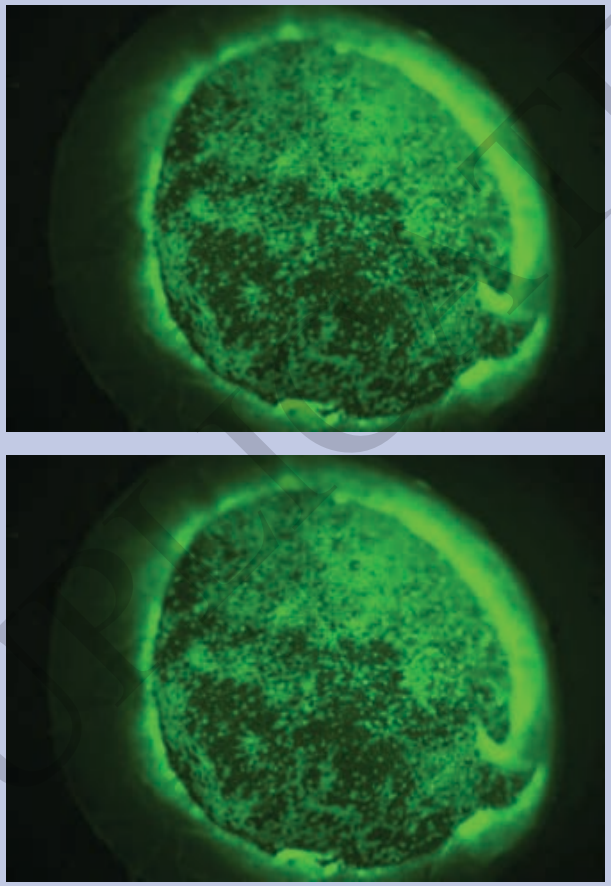

Figure 2. Images of cell viability in epidermal microdome. *Reprinted with permission from KCI Licensing, Inc.*

Keypoints

- Epidermal grafting utilizes autologous skin, yet eliminates most of the drawbacks of split-thickness skin grafts when only epidermis is needed.[1,2]
- There are several reports of the successful harvesting of epidermal grafts in burns and chronic wounds.[6-11]
- The majority of these cases employed a suction blister epidermal grafting (SBEG) technique during which epidermal blisters were raised using a suction apparatus, and epidermis was harvested using a free hand blade technique.

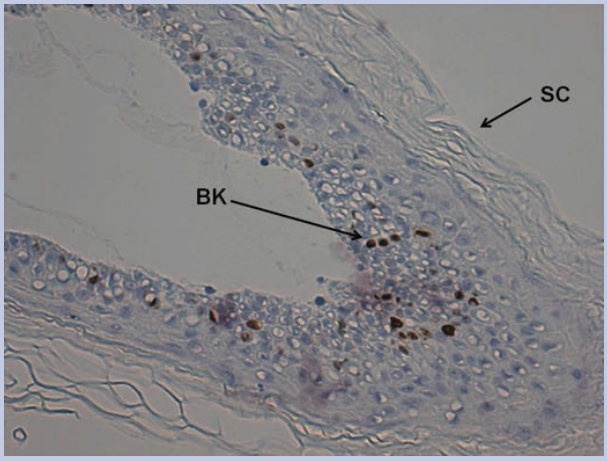

Figure 3. Formation of the epidermal microdomes at dermaepidermal junction. Hematoxylin staining of an epidermal microdome (blue), demonstrates the layers of the epidermis. Brown staining shows position of basal keratinocytes. SC: stratum corneum; BK: basal keratinocytes. *Reprinted with permission from KCI Licensing, Inc.*

Keypoints

- Advantages of epidermal grafting over traditional split-thickness skin grafting include little or no patient discomfort during harvesting, obviating the need for anesthesia; the option of performing the procedure in an outpatient setting vs an operating room; a superficial donor site wound that heals within 2 to 4 weeks with minimal scarring; and a simplified procedure that requires no surgical training.

sults in minimal patient discomfort and alleviated need for anesthesia during the procedure. The purpose of this paper is to review the use of epidermal grafting in the management of wounds and to describe the automated technique of epidermal harvesting.

Materials and Methods

The wound selected for grafting should have a clean granulating base free of nonviable tissue. If indicated, it should be debrided prior to application of epidermal microdomes, ensuring that complete hemostasis has been achieved prior to applying the grafts. The harvester and its straps have been optimized for use on the inner thigh, where the epidermis has experienced minimal sun exposure and is optimal for forming epidermal micrografts. Preparation of the donor site begins by clipping any hair on the inner thigh. Hair should not be removed using a razor. The skin is then prepared using isopropyl alcohol or a similar preparing agent. The author has avoided the use of betadine as it may result in the harvester sticking to the skin causing patient discomfort upon removal. The harvester is then placed with the curved blade side upwards (Figure 4A) and secured with the Velcro strap provided.

The vacuum head is then applied to the harvester ensuring there is an adequate seal (Figure 4B). One technique, in the author's experience, for accomplishing a good seal is to press on the alternate corners of the vacuum head/harvester.

Next, the unit is powered on, and pressing the start button begins the process of producing the epidermal microdomes. The system heats the skin at 37°C to 41°C and applies -400 mm Hg to -500 mm Hg of negative pressure. The physician then observes the skin through the view window. The harvesting process is complete when round epidermal microdomes form (Figure 1). Microdome preparation may take between 15 to 60 minutes.

Harvesting begins by turning off the unit, removing the vacuum head, and inserting a dressing into the harvester to collect the epidermal microdomes. In his practice, the author uses a foam dressing (Mepitel One, Molnlycke Healthcare, Gothenburg, Sweden) for exudative wounds and a transparent dressing (Tegaderm, 3M, St. Paul, MN) for wounds with low levels of drainage. If employing a transparent dressing, the suggested method is to gently rub the dressing against the epidermal microdomes. The blue handle operating the blades is then pulled back until an audible click is heard. The blades are engaged when the handle is lowered (Figure 4C). Gently removing the dressing from the harvester reveals the adherent epidermal microdomes (Figures 4D). The dressing can then be transferred to the recipient site. If a transparent dressing is used to harvest the grafts, the author suggests using an 18 gauge blade to perforate the dressing for exudative wounds (Figure 4E).

The epidermal microdomes should be secured in place using compression wrapping, a bolster dressing, or with negative pressure wound therapy, similar to the treatment of a STSG. The donor site should be covered with a transparent dressing (Figure 4F).

Discussion

Epidermal grafting has been shown to be effective in the management of acute surgical wounds and chronic ulcers, particularly diabetic and venous leg ulcerations.[4,5] Advantages of epidermal grafting over traditional split-thickness skin grafting include little or no pa-

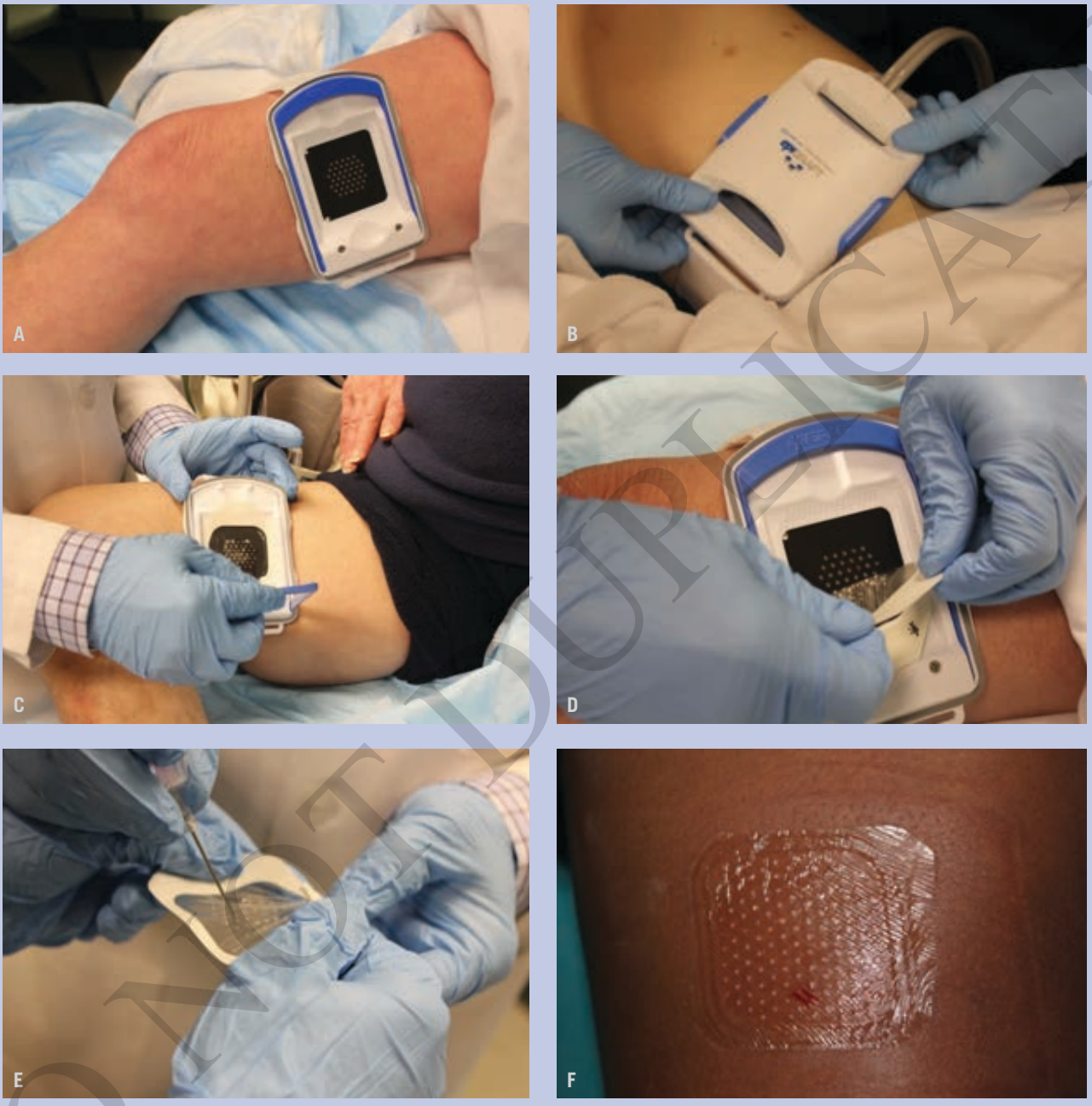

Figure 4. (A) The epidermal harvesting system in place. (B) Securing the vacuum head to the harvester. (C) Activating the blades. (D) Removal of the dressing. (E) Perforating the transparent dressing. (F) The transparent dressing on the donor site.

tient discomfort during harvesting, obviating the need for anesthesia; the option of performing the procedure in an outpatient setting vs an operating room; a superficial donor site wound that heals within 2 to 4 weeks with minimal scarring; and a simplified procedure that requires no surgical training.

Epidermal grafts have also been shown to be effective in the management of skin breakdown secondary to pyoderma gangrenosum.[14] Patients with pyoderma gangrenosum are not candidates for STSGs because of the cutaneous phenomenon of pathergy and the potential to produce a chronic wound at the donor site in this population. Because the device harvests only epidermis, this epidermal harvesting technique does not result in pathergy

Keypoints

- In a case series of patients treated in a wound clinic at Hospital Bernard Mevs Project Medishare in Port-au-Prince, Haiti in 2012,[15] 6 out of 7 patients had a significant reduction in wound surface area in 4 weeks, including 1 patient with lymphatic filariasis who achieved complete closure.[15]
- Additional controlled studies evaluating the safety and efficacy of this technique are currently underway.

at the donor site. In a reported case series of 5 patients, the donor sites healed in all of the patients without complication.

The automated SBEG system has simplified suction blister harvesting, making it available to the wound care clinician to harvest epidermal grafts as a reconstructive option for wounds. One of the first documented uses of the automated epidermal harvesting system was reported in a case series of patients treated in a wound clinic at Hospital Bernard Mevs Project Medishare in Port-au-Prince, Haiti in 2012.[15] In this series, 6 out of 7 patients had a significant reduction in wound surface area in 4 weeks, including 1 patient with lymphatic filariasis who achieved complete closure.[15] Results from this series have prompted these investigators to participate in a larger prospective, randomized, controlled multicenter trial evaluating epidermal grafting in venous leg ulcers.

Conclusion

Epidermal grafting has been reported to be effective in pigmentation disorders and the management of wounds. The commercially available automated epidermal harvesting system allows quick harvest and transfer of the epidermal micrografts in an office setting with minimal patient discomfort and donor site pain and no need for anesthesia. Additional controlled studies evaluating the safety and efficacy of this technique are currently underway.

Reference

1. Rusfianti M, Wirohadidjodjo YW. Dermatosurgical techniques for repigmentation of vitiligo. *Int J Dermatol*. 2006;45(4):411-417.
2. Njoo MD, Westerhof W, Bos JD, Bossuyt PM. A systematic review of autologous transplantation methods in vitiligo. *Arch Dermatol.* 1998;134(12):1543-1549.
3. Kiistala U, Mustakallio KK. In-vivo separation of epidermis by production of suction blisters. *Lancet*. 1964;1(7348):1444-1445.
4. Gupta S, Shroff S, Gupta S. Modified technique of suction blistering for epidermal grafting in vitiligo. *Int J Dermatol*. 1999;38(4):306-309.
5. Ramos JV, Schmidt M, Wu SC. Epidermal skin grafts for the treatment of chronic lower extremity ulcers. *Podiatry Manage*. 2013;32(9):95-104.
6. Burm JS, Rhee SC, Kim YW. Superficial dermabrasion and suction blister epidermal grafting for postburn dyspigmentation in Asian skin. *Dermatol Surg*. 2007;33(3):326-332.
7. Yamaguchi Y, Yoshida S, Sumikawa Y et al. Rapid healing of intractable diabetic foot ulcers with exposed bones following a novel therapy of exposing bone marrow cells and then grafting epidermal sheets. *Br J Dermatol*. 2004;151(5):1019-1028.
8. Costanzo U, Streit M, Braathen LR. Autologous suction blister grafting for chronic leg ulcers. *J Eur Acad Dermatol Venereol*. 2008;22(1):7-10.
9. Ichiki Y, Kitajima Y. Successful treatment of scleroderma-related cutaneous ulcer with suction blister grafting. *Rheumatol Int*. 2008;28:299-301.
10. Hanafusa T, Yamaguchi Y, Katayama I. Intractable wounds caused by arteriosclerosis obliterans with end-stage renal disease treated by aggressive debridement and epidermal grafting. *J Am Acad Dermatol.* 2007;57(2):322-326.
11. Yamaguchi Y, Sumikawa Y, Yoshida S, Kubo T, Yoshikawa K, Itami S. Prevention of amputation caused by rheumatic diseases following a novel therapy of exposing bone marrow, occlusive dressing and subsequent epidermal grafting. *Br J Dermatol*. 2005;152(4):664-672.
12. Osborne SN, Schmidt MA, Harper JR. An automated and minimally invasive tool for generating autologous viable epidermal micrografts. *Adv Skin Wound Care*. In press.
13. Osborne SN, Schmidt MA, Derrick K, Harper JR. Epidermal micrografts produced via an automated and minimally invasive tool form at the dermal/epidermal junction, and contain proliferative cells that secrete wound healing growth factors. *Adv Skin Wound Care*. In press.
14. Richmond, NA, Lamel SA, Braun LR, Vivas AC, Serena T, Kirsner RS. Epidermal grafting using a novel suction blister-harvesting system for the treatment of pyoderma gangrenosum. *JAMA Dermatol*. 2014;150(9):999-1000.
15. Serena T, Francius A, Taylor C, Macdonald J. Use of a novel epidermal harvesting system in resource poor countries. Oral abstract presented at: The Symposium on Advanced Wound Care Spring; April 23-27, 2014; Orlando, FL.