

# The Use of Human Amnion/Chorion Membrane in the Clinical Setting for Lower Extremity Repair: A Review



Charles M. Zelen, DPM<sup>a,\*</sup>, Robert J. Snyder, DPM, MSc, CWS<sup>b</sup>,  
Thomas E. Serena, MD<sup>c</sup>, William W. Li, MD<sup>d</sup>

## KEYWORDS

- Amniotic membrane • Dehydrated human amnion/chorion membrane
- Growth factors • Wound care

## KEY POINTS

- Amniotic membrane composed of amnion and chorion has been recognized for its use as a facilitator of wound healing for more than 100 years.
- Amniotic membrane-based products have various therapeutic applications in the foot and ankle, including the treatment of chronic wounds, fasciitis, and tendonitis.
- Several products containing various components of amniotic membrane are available, but for most there are limited clinical and scientific data.
- Dehydrated human amnion/chorion membrane contains an array of growth factors known to play critical roles in the physiologic processes of normal healing and tissue regeneration.

## INTRODUCTION

Normal wound healing occurs in a well-orchestrated and predictable sequence of events including hemostasis, inflammation, proliferation, and remodeling. These inter-related physiologic processes create a reparative microenvironment characterized by high initial levels of growth factors and other soluble mediators of cell signaling;

---

Disclosures: Dr Zelen: The Professional Education and Research Institute of which he is Medical Director has received funding from MiMedx for completion of studies related to dHACM; Dr. Snyder: Has provided consultative services to MiMedx. Dr. Serena has served as a principal investigator for MiMedx and has received research funds. Dr. Li has provided consultative services to MiMedx.

<sup>a</sup> Professional Education and Research Institute, Inc, Foot and Ankle Associates of Southwest Virginia, 222 Walnut Avenue, Roanoke, VA 24016, USA; <sup>b</sup> Barry University School of Podiatric Medicine, 11300 NE 2nd Avenue, Miami Shores, FL 33161, USA; <sup>c</sup> SerenaGroup Wound and Hyperbaric Centers, 90 Sherman Street, Cambridge, MA 02140, USA; <sup>d</sup> The Angiogenesis Foundation, PO Box 425007, Cambridge, MA 02142, USA

\* Corresponding author.

E-mail address: [cmzelen@periedu.com](mailto:cmzelen@periedu.com)

Clin Podiatr Med Surg 32 (2015) 135–146  
<http://dx.doi.org/10.1016/j.cpm.2014.09.002>

[podiatric.theclinics.com](http://podiatric.theclinics.com)

0891-8422/15/\$ – see front matter © 2015 Elsevier Inc. All rights reserved.

controlled levels of proteases and bacteria; and functional fibroblasts, keratinocytes, and vascular endothelial cells.<sup>1</sup>

Cell-mediated regeneration of extracellular matrix (ECM), the largest component of dermal skin layer, remains an integral part of this complex dynamic.<sup>1</sup> In acute wounds the provisional wound matrix composed of fibrin and fibronectin provides a scaffold to direct cells into the site of injury, which then participates in secreting ECM. The ECM forms communications signals with cells and between cells through a process known as dynamic reciprocity.<sup>1</sup>

Angiogenesis, the formation of new blood vessels, is another critical process to normal wound repair.<sup>2</sup> Activated by growth factors released by platelets, inflammatory cells, and fibroblasts, vascular endothelial cells sprout and form new capillary channels in the wound bed. Together with the provisional matrix, these angiogenic vessels comprise the granulation tissue heralding a successfully healing wound. Many advanced wound healing modalities, ranging from negative pressure to growth factor therapy to living skin equivalents, are designed to stimulate angiogenesis and accelerate wound repair.

More recently, regenerative mechanisms have been elucidated in wound healing. A variety of stem cells may play a role in wound repair, including mesenchymal stem cells, adipose stromal cells, and endothelial progenitor cells.<sup>3-5</sup> These cells are mobilized, recruited, and homed to sites of injury by soluble mediators generated by the wound healing cascade. A growing number of regenerative therapies in development exploit these stem cells as a novel wound healing strategy.

In contrast, chronic, or delayed healing, wounds are characterized by an aberrant and hostile wound microenvironment, including persistent inflammation, cell senescence, growth factor deficiencies, bioburden, and increased levels of destructive proteases.<sup>1</sup> These factors impede angiogenesis, granulation, and epithelialization.<sup>1,6</sup> Despite multiple causes of chronic wounds (eg, diabetes, venous insufficiency, peripheral arterial disease, and pressure) virtually all chronic wounds share one or more of these common pathologic features.

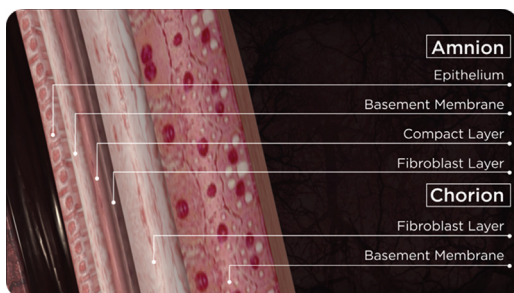
Many advanced wound management interventions are clinically used to support or promote healing of chronic wounds. These interventions include recombinant growth factors, living skin equivalents, negative pressure therapy, low-frequency ultrasonography, and more recently products derived from amniotic membrane. This article reviews recent scientific data and clinical findings related to amniotic membrane in wound healing.

## AMNIOTIC MEMBRANE AS A THERAPEUTIC INTERVENTION

Human amniotic membrane is a reproductive tissue representing the innermost lining of the placenta. Two distinct layers, the amnion and chorion, become fused at approximately 3 months of gestation (**Fig. 1**). These layers serve to protect the fetus during growth in the uterus. Among the key functions of amniotic membrane are:

- Its immunologically privileged state
- Reservoir of multiple growth factors involved with tissue growth and regeneration
- Antiinflammatory properties

Such properties confer remarkable therapeutic potential for amniotic membrane for wound healing, tissue repair, and regenerative therapy.<sup>7-11</sup> Native human amnion/chorion membrane contains growth factors, such as epidermal growth factor (EGF), basic fibroblast growth factor (bFGF), keratinocyte growth factor (KGF), vascular EGF (VEGF), transforming growth factors (TGFs); nerve growth factor (NGF), and



**Fig. 1.** The amniotic membrane consists of 2 conjoined layers: the amnion and chorion.

many chemokines known to be important for the healing of both acute and chronic wounds.<sup>12,13</sup> Note that amniotic membranes are avascular.<sup>14</sup>

The amnion is composed of 5 distinct layers<sup>15,16</sup>:

- The epithelium
- A basement membrane
- The compact layer
- A fibroblast layer
- The intermediate or spongy layer

The chorion<sup>17</sup>:

- Is 3 to 4 times thicker than the amnion
- Is composed of a cellular layer, a thick reticular layer, a pseudobasement membrane, and a trophoblast layer, which remains adhered to the maternal decidua

In an amnion/chorion graft, the chorion contributes 75% of the overall growth factor content.<sup>18</sup>

The source of amniotic membrane for wound management is donor placenta. However, fresh amniotic grafts are not practical for routine clinical use in the wound clinic, so commercially available amniotic membrane products undergo a range of processing and preservation techniques, including dehydration and cryopreservation, and represent a range of membrane configurations, from amnion alone to amnion and chorion.

Most data, both scientific and clinical, supporting the benefit of amniotic membrane for wound repair have been obtained from studies of dehydrated human amnion/chorion membrane (dHACM) allograft (EpiFix, AmnioFix, MiMedx Group, Marietta, GA), so these data are the focus of this article.<sup>18-31</sup> This allograft originates from human placentas from low-risk patients planning scheduled caesarean delivery donated under informed consent. All donors are prescreened and tested to be free of infectious diseases, including human immunodeficiency virus, human T-lymphotropic virus, hepatitis B and C, and syphilis. The proprietary PURION process gently cleanses and washes the membranes to reduce bioburden, with minimal tissue manipulation to maintain structural integrity, and dehydrates the tissue. This procedure makes it distinct from products that are cryopreserved, or cross-linked and frozen. Allografts that have undergone this dehydration process have no viable cells and retain a 5-year shelf life under ambient conditions.

The dHACM allograft is regulated under Section 361 of the Public Health Service Act by the United States Food and Drug Administration. It is intended for homologous use, which is defined by regulatory authorities as “the repair, reconstruction, replacement, or supplementation of a recipient’s cells or tissues with a human cell, tissue and

cellular, and/or tissue based product (HCT/Ps) that performs the same basic function or functions in the recipient as in the donor.”<sup>32</sup>

### AMNIOTIC MEMBRANE MECHANISMS OF ACTION IN WOUND HEALING

Although the full spectrum of wound repair induced by amniotic membrane has not yet been defined, several key mechanism of action have been elucidated: enzyme-linked immunosorbent assay (ELISA) assays performed on samples of dHACM have shown quantifiable levels of the following growth factors<sup>20</sup>:

- Platelet-derived growth factor (PDGF)–AA and PDGF-BB
- TGF- $\alpha$  and TGF- $\beta$ 1
- bFGF
- EGF
- Granulocyte colony stimulating factor (GCSF)

The ELISA assays<sup>20</sup> also identified the presence of interleukin (IL)-4, IL-6, IL-8, and IL-10, which suppress inflammation and may contribute to dHACM's immune-privileged properties,<sup>33</sup> and tissue inhibitors of metalloproteinase (TIMP)-1, TIMP-2, and TIMP-4, which neutralize the destructive biological effects of matrix metalloproteinases 2 and 9, which are often overexpressed in chronic wounds. The presence and amount of signaling molecules, including 14 cytokines and 10 chemokines known to regulate inflammation, and 12 cytokines known to regulate wound healing processes present in dHACM, are presented in **Table 1**.

There are several amniotic membrane products of various configurations being marketed as treatments of diabetic foot ulcers (**Table 2**). Because some products comprise only a single-layered amnion, without chorion, an *in vitro* study<sup>18</sup> compared growth factor levels from single-layered therapy with multilayered allografts composed of both amnion and chorion (eg, dHACM). The total cytokine content contributed by chorion was higher than that contributed by amnion alone. In all cases, bilayered (amnion plus chorion) allograft contained significantly more growth factors than the single-layer amnion grafts. The growth factors present in dHACM have been shown to induce human dermal fibroblast proliferation, which is relevant to wound healing, especially in diabetic feet.<sup>19</sup>

Studies of amniotic membrane using dHACM showed the ability of the tissue to recruit multiple stem cells relevant to wound repair and regeneration. Both stromal cell-derived factor 1 (SDF-1) and chemokine receptor type 4 (CXCR4), which are stem cell recruitment and homing factors, are present in dHACM. *In vitro* studies confirmed that the dehydrated allograft can attract stem cells to stimulate the migration of mesenchymal stem cells.<sup>19</sup> *In vivo* studies showed that stem cells homed to sites of neovascularization, reflecting their role as endothelial progenitor cells.<sup>19–21</sup> Unlike cellular therapies that deliver cells with so-called stemlike characteristics, the dHACM releases factors that recruited endogenous stem cells, suggesting bona fide regenerative capability when used in wound management.

Studies of dHACM grafts also clearly showed their ability to induce angiogenesis, associated with the presence of multiple proangiogenic factors present in and released by the dehydrated tissue with retained biological activity.<sup>21</sup> Furthermore, studies using the conditioned media of dHACM stimulated the upregulated production of endogenous angiogenic factors by endothelial cells, supporting a paracrine amplifying effect by the graft to stimulate wound angiogenesis.<sup>21</sup>

These recently defined mechanisms of an amnion/chorion platform used in wound management help explain the clinical benefits of dHACM.

**Table 1**  
Cytokines and chemokines in dHACM

Regulators of Wound Healing in EpiFix and AmnioFix	
Cytokines	
Ang	IGFBP-2
ANG-2	IGFBP-3
bFGF	IGFBP-4
BMP-5	IGFBP-6
BDNF	$\beta$ -NGF
EG-VEGF	PIGF
EGF	PDGF-AA
FGF-4	PDGF-BB
KGF; FGF-7	TGF- $\alpha$
GH	TGF- $\beta$ 1
HB-EGF	VEGF
HGF	TIMP-1
IGF-1	TIMP-2
IGFBP-1	TIMP-4
Regulators of Inflammation in EpiFix and AmnioFix	
Cytokines	Chemokines
GCSF	BLC
GM-CSF	Eotaxin-2
GDF-15	I-309
IFN $\gamma$	IL-8
IL-1 $\alpha$	IL-16
IL-1 $\beta$	MCP-1
IL-1ra	MIG
IL-4,5,6,7,10	MIP-1 $\alpha$
IL-12p40	MIP-1 $\beta$
IL-12p70	MIP-1d
IL-15	RANTES
IL-17	—
MCSF	—
OPG	—

*Abbreviations:* Ang, angiopoietin; BDNF, brain-derived neurotrophic factor; BLC, B-lymphocyte chemoattractant; BMP, bone morphogenetic protein; GDF, growth differentiation factor; GH, growth hormone; GM-CSF, granulocyte-macrophage colony stimulating factor; HGF, hepatocyte growth factor; IFN $\gamma$ , interferon gamma; IGF, insulin-like growth factor; IGFBP, insulin-like growth factor-binding protein; MCP, monocyte chemotactic protein; MCSF, macrophage colony-stimulating factor; MIG, monokine induced by gamma-interferon; MIP, macrophage inflammatory Protein; OPG, osteoprotegerin; PIGF, placental growth factor; RANTES, regulated on activation, normal T cell expressed and secreted.

## CLINICAL APPLICATION OF AMNIOTIC MEMBRANE FOR TREATMENT OF CHRONIC WOUNDS

Chronic wounds, such as diabetic neuropathic foot ulcers, venous or arterial insufficiency ulcers, and pressure ulcers lead to disability, morbidity, and accelerated

Product	Preservation and Configuration	Peer-reviewed Publications of Effectiveness for DFU
EpiFix	dHACM	Rapidly expanding body of evidence in the peer-reviewed literature including basic science, case studies, case series and RCTs
AmnioClear	Dehydrated amnion/chorion laminate	None
Neox100	Cryopreserved: single-layer amnion	None
Grafix	Cryopreserved: single-layer amnion	Limited to 1 randomized study, N = 20 <sup>39</sup>
BioDfactor	Cryopreserved: liquid amnion	None
Flograft		Limited to case series of N = 20

*Abbreviations:* DFU, diabetic foot ulcer; RCT, randomized controlled trial.

mortality. An evidence-based, patient-centered, multidisciplinary approach is central to optimizing the treatment of nonhealing wounds.<sup>34</sup> However, many ulcers remain refractory to standard treatment algorithms. A meta-analysis<sup>35</sup> of standard wound care, defined as debridement, offloading, and use of saline-gauze dressings, examined 10 control groups from clinical trials of patients with diabetic lower extremity wounds. The weighted mean rates of neuropathic ulcer healing were 24.2% at 12 weeks, and 30.9% at 20 weeks. These data provide realistic benchmarks for expectations of ulcer healing over time, and clearly show that standard care is often not satisfactory for healing foot ulcers in patients with diabetes. Venous leg ulcers are also slow to heal, with less than two-thirds (62%) of all venous leg ulcers being healed by 24 weeks using standard care alone.<sup>36</sup> When ulcerations fail to respond to standard therapies over a reasonable period of time, clinicians may select advanced modalities with a clear scientific rationale, such as amniotic membrane, to promote accelerated healing.

## CLINICAL RESEARCH SUMMARY

### *Early Clinical Case Series*

The early literature for amniotic membrane commenced with published case reports<sup>22</sup> describing a prospective series of 3 recalcitrant patients successfully treated with dHACM. The patients were diagnosed with insulin-dependent or non-insulin-dependent diabetes and were receiving conservative care for treatment of a foot ulcer. Advanced therapy was considered because their wound size had not decreased by 50% after 4 weeks of standard care. All patients went on to completely heal with dHACM therapy.

Another case series<sup>25</sup> described 4 patients with refractory wounds that were initially referred for a definitive plastic surgery procedure (ie, flap reconstruction surgery) but received dHACM instead. Healing was observed in a variety of wound types with 1 to 3 applications of the dehydrated graft, eliminating the need for surgical intervention. In each case, a large reduction in wound size was observed after the initial application of dHACM, and the ulcers did not recur in long-term follow-up.

In another retrospective case series of 5 patients with recalcitrant wounds (failure to heal at least 50% for a period of a month)<sup>23</sup> ulcers treated with dHACM showed improved healing accompanied by a change in healing trajectories compared with those documented before application.

### **Randomized Controlled Trials**

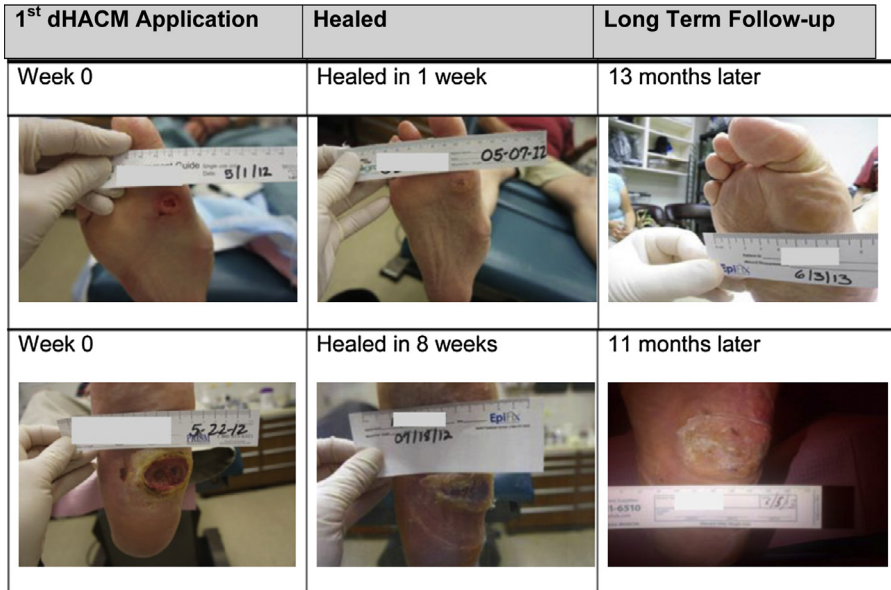
Zelen and colleagues<sup>26</sup> conducted a prospective, randomized, single-center clinical trial to compare healing characteristics of diabetic foot ulcers treated with dHACM versus standard of care. Patients were randomized to receive standard of care alone or standard of care with the addition of dHACM. Wound size reduction and rates of complete healing were evaluated after 4 and 6 weeks. At 4 weeks, wounds reduced in size by a mean of  $32.0\% \pm 43.7\%$  in the standard of care arm ( $n = 12$ ) versus  $97.1\% \pm 7.0\%$  ( $P \leq .001$ ) in the dHACM group ( $n = 13$ ). However, at 6 weeks, in the standard of care group mean wound size had increased  $1.8\% \pm 0.3\%$  versus a mean wound size reduction of  $98.4\% \pm 5.8\%$  in the dHACM group ( $P \leq .001$ ). After 4 and 6 weeks of treatment, the overall healing rates for dHACM were 77% and 92% respectively, compared with 0% and 8.0% respectively for the standard of care ( $P \leq .001$ ). Because of the large effect size, despite the small study size ( $n = 25$ ), statistical significance between the groups was reached ( $P < .001$ ), and a decision was made to terminate the study early for ethical reasons.

During the initial study 11 of 12 patients receiving standard of care remained unhealed after 6 weeks. These nonhealers ( $n = 11$ ) were then treated with dHACM. A retrospective analysis was conducted to determine the effectiveness dHACM in these patients.<sup>27</sup> As anticipated, a similar accelerated healing effect was observed in these individuals. Mean wound chronicity was  $21.1 \pm 12.4$  weeks and a mean wound size of  $4.7 \pm 5.0$  cm<sup>2</sup> at initiation of dHACM treatment. Complete healing was achieved in 55% by 4 weeks, 64% by 6 weeks, and 91% by 12 weeks with biweekly applications.

Wound recidivism is often a problem even following the use of advanced modalities. For this reason, a retrospective study<sup>28</sup> was performed on all patients who received dHACM and healed in the aforementioned trials. Patients ( $N = 18$ ) were available for follow-up evaluation at 9 to 12 months after primary healing. Seventeen of 18 (94.4%) ulcers remained fully healed at this later time point, strongly suggesting durability of wound repair (Fig. 2).

In order to optimize the quality of clinical care it is important to establish the ideal application frequency for advanced treatment modalities. Therefore, a prospective, randomized, comparative study of 40 patients with diabetic foot ulcers of greater than or equal to 4 weeks' duration that did not heal with standard treatment were randomized to receive weekly ( $n = 20$ ) versus biweekly ( $n = 20$ ) application of dHACM, in addition to nonadherent, moist wound healing, compression wraps, and offloading.<sup>29</sup> During the 12-week study period, 92.5% (37 of 40) ulcers completely healed. Mean time to heal was  $4.1 \pm 2.9$  weeks in the biweekly group versus  $2.4 \pm 1.8$  weeks in the weekly group ( $P = .039$ ). Complete healing occurred in 50% versus 90% by 4 weeks in the biweekly versus the weekly groups, respectively. Number of grafts applied were similar in both groups ( $P = .841$ ). In summary, the difference in healing rates for weekly versus biweekly applications of dHACM showed a clear clinical preference for weekly application of the material, because those wounds receiving weekly application of dHACM healed more than 40% faster. The faster healing with weekly application also shows an economic advantage given that the patients receiving weekly application required fewer treatment visits and dressing changes at the wound healing center.

Venous leg ulcers represent the largest category of ambulatory wounds in the United States and are responsible for causing pain and disability for thousands of patients. A multicenter randomized controlled clinical trial<sup>30</sup> ( $N = 84$ ) evaluated the use of dHACM and multilayered compression therapy versus multilayered therapy alone in the treatment of venous leg ulcers. Fifty-three patients were randomized to receive



**Fig. 2.** Examples of wounds at first dHACM application, when healed, and at long-term follow-up visit.

the dHACM allograft and 31 were randomized into the control group. The primary study outcome was the proportion of wounds achieving 40% closure at 4 weeks in patients treated with dHACM and multilayer compression versus patients treated with multilayer compression without dHACM. At 4 weeks, 62% in the dHACM group and 32% of controls showed greater than 40% wound closure ( $P = .005$ ), thus showing a significant advantage in the dHACM-treated group compared with the control group at a 4-week surrogate end point. After 4 weeks, wounds treated with dHACM had reduced in size a mean of 48.1% compared with 19.0% for controls. This study showed that venous leg ulcers treated with dHACM allograft had a significant improvement in healing at 4 weeks compared with multilayered compression alone.

### ***Other Clinical Indications in Distal Extremities***

Sheets of amniotic membrane have been used to decrease scarring and improve function in various soft tissue and bone procedures of the foot and ankle.<sup>37</sup> In addition, amniotic membrane can also be delivered in an injectable micronized form. The injectable form can also be used for wound healing applications, including tunneling or deep wounds, but there is also evidence that the material can be used for treatment of tendon and ligament disorders of the foot and ankle.<sup>31</sup>

Tendon and ligament disorders are common conditions seen by many clinical specialties and are responsible for much pain and morbidity, and the healing process is often prolonged and incomplete.<sup>38</sup> Growth factors contained in dHACM including EGF, TGF- $\beta$ , and fibroblast growth factor (FGF) are known to stimulate epithelial cell migration and proliferation, whereas PDGF-A and PDGF-B stimulate many metabolic processes, including general protein and collagen synthesis, collagenase activity, and chemotaxis of fibroblasts and of smooth muscle cells.<sup>7,33</sup> TGF- $\beta$  has been shown to significantly increase type I collagen production by tendon sheath fibroblasts.<sup>7</sup>



Delivering these growth factors to areas of tendon or ligament damage via micronized dHACM injection may allow more rapid and complete healing.

Anecdotal and unpublished data suggest that dHACM injection may be a viable treatment of a variety of tendon and ligament injuries. A prospective, randomized, single-center clinical trial was performed to examine efficacy of dHACM injection for the treatment of plantar fasciitis.<sup>31</sup> The dHACM used in the trial went through a micronization process creating a dHACM powder that was dispersed into suspension with sterile 0.9% saline solution for injection. On study enrollment all patients had been diagnosed with plantar fasciitis for greater than 2 months and had failed at least 3 conservative treatment regimens, including corticosteroid injection. Forty-five patients were randomized to receive injection of 2 mL of 0.5% Marcaine plain, then either 1.25 mL of saline (controls), 0.5 mL of dHACM, or 1.25 mL of dHACM. Follow-up visits occurred over 8 weeks to measure function, pain, and functional health and well-being. Within 1 week of treatment and during the study period significant improvement in plantar fasciitis symptoms was observed in patients receiving either amount of dHACM versus controls. American Orthopedic Foot and Ankle Society (AOFAS) hind-foot scores increased by a mean of only  $2.2 \pm 17.4$  points for controls versus  $38.7 \pm 11.4$  points for those receiving 0.5 mL of dHACM ( $P < .001$ ) and  $33.7 \pm 14.0$  points for those receiving 1.25 mL of dHACM ( $P < .001$ ). After 8 weeks AOFAS hindfoot scores increased by a mean of  $12.9 \pm 16.9$  points for controls versus  $51.6 \pm 10.1$  and  $53.3 \pm 9.4$  for those receiving 0.5 mL and 1.25 mL of dHACM respectively (both  $P < .001$ ). Treatment response was not significantly different for patients receiving 0.5 mL versus 1.25 mL of dHACM. Patients receiving dHACM experienced significantly reduced pain over the study period, whereas this was not observed in controls.

Taken together, these clinical results, combined with the scientific data on mechanism of action, suggest that dHACM has potent and efficacious activity as a wound healing intervention in soft tissue disorders of the lower extremity.

## SUMMARY

Unsuccessful healing represents a significant medical dilemma for both patients and clinicians and create a financial burden on the health care system. Despite the efforts of physicians, many injuries fail to heal with standard care alone. For decades human amniotic membrane composed of both amnion and chorion has shown remarkable therapeutic potential, but only recent preservation methods have allowed its widespread use. Variations in configurations and the ability to micronize the material allow clinical uses that were previously not possible. Although there are limited data available regarding most amniotic membrane-based products, there is substantial preclinical and clinical evidence supporting the rationale and effectiveness of dHACM allograft as a treatment modality. The rapidly growing body of evidence suggests that the properties inherent in dHACM promote tissue regeneration and healing, recruiting patients' own stem cells into the wounded area. Randomized controlled trials evaluating dHACM now include more than 200 patients collectively and the results consistently show improved healing. Use of dHACM has been shown to be more clinically effective and cost-effective than other frequently used advanced wound care products.<sup>38</sup> This cost-effectiveness results from dHACM showing higher healing rates and more rapid healing than other advanced wound care products. Cost-effectiveness is also enhanced through the availability of grafts of multiple sizes, which reduces wastage, and through ease of handling and storage for clinical use. Ongoing and future studies will further define and establish the value of amniotic membrane for chronic tissue repair and regeneration.

## REFERENCES

1. Schultz GS, Davidson JM, Kirsner RS, et al. Dynamic reciprocity in the wound microenvironment. *Wound Repair Regen* 2011;19(2):134–48.
2. Li WW, Talcott KE, Zhai AW, et al. The role of therapeutic angiogenesis in tissue repair and regeneration. *Adv Skin Wound Care* 2005;18(9):491–500.
3. Chen Z, Wang Y, Shi C. Therapeutic implications of newly identified stem cell populations from the skin dermis. *Cell Transplant* 2014. [Epub ahead of print].
4. Kokai LE, Marra K, Rubin JP. Adipose stem cells: biology and clinical applications for tissue repair and regeneration. *Transl Res* 2014;163(4):399–408.
5. Asahara T, Masuda H, Takahashi T, et al. Bone marrow origin of endothelial progenitor cells responsible for postnatal vasculogenesis in physiological and pathological neovascularization. *Circ Res* 1999;85(3):221–8.
6. Guo S, DiPietro LA. Factors affecting wound healing. *J Dent Res* 2010;89(3):219–29. <http://dx.doi.org/10.1177/0022034509359125>.
7. Parolini O, Solomon A, Evangelista M, et al. Human term placenta as a therapeutic agent: from the first clinical applications to future perspectives. In: Berven E, editor. *Human placenta: structure and development*. Hauppauge (NY): Nova Science Publishers; 2010. p. 1–48.
8. Baradaran-Rafii A, Aghayan H, Arjmand B, et al. Amniotic membrane transplantation. *Iran J Ophthalmic Res* 2007;2(1):58–75.
9. Bennett JP, Matthews R, Faulk WP. Treatment of chronic ulceration of the legs with human amnion. *Lancet* 1980;1:1153–6.
10. John T. Human amniotic membrane transplantation: past, present, and future. *Ophthalmol Clin North Am* 2003;16:43–65.
11. Tao H, Fan H. Implantation of amniotic membrane to reduce postlaminectomy epidural adhesions. *Eur Spine J* 2009;18(8):1202–12.
12. Lopez-Valladares MJ, Rodriguez-Ares MT, Tourino R, et al. Donor age and gestational age influence on growth factor levels in human amniotic membrane. *Acta Ophthalmol* 2010;88(6):e211–6.
13. Russo A, Bonci P, Bonci P. The effects of different preservation processes on the total protein and growth factor content in a new biological product developed from human amniotic membrane. *Cell Tissue Bank* 2012;13(2):353–61.
14. Dua HS, Gomes JA, King AJ, et al. The amniotic membrane in ophthalmology. *Surv Ophthalmol* 2004;49(1):51–77.
15. Daniel J, Tofe R, Spencer R, et al. Placental tissue grafts. US Patent; 2013. 8,409,626.
16. Parry S, Strauss JF. Premature rupture of the fetal membranes. *N Engl J Med* 1998;338(10):663–70.
17. Chua WK, Oyen ML. Do we know the strength of the chorioamnion? A critical review and analysis. *Eur J Obstet Gynecol Reprod Biol* 2009;144(Suppl 1):S128–33.
18. Koob TJ, Lim JJ, Zabek N, et al. Cytokines in single layer amnion allografts compared to multi-layered amnion/chorion allografts for wound healing. *J Biomed Mater Res B Appl Biomater* 2014. <http://dx.doi.org/10.1002/jbm.b.33265>.
19. Koob TJ, Lim JJ, Masee M, et al. Properties of dehydrated human amnion/chorion composite grafts: implications for wound repair and soft tissue regeneration. *J Biomed Mater Res B Appl Biomater* 2014;102(6):1353–62. <http://dx.doi.org/10.1002/jbm.b.33141>.

20. Koob TJ, Rennert R, Zabek N, et al. Biological properties of dehydrated human amnion/chorion composite graft: implications for chronic wound healing. *Int Wound J* 2013;10(5):493–500.
21. Koob TJ, Lim JJ, Masee M, et al. Angiogenic properties of dehydrated human amnion/chorion allografts: therapeutic potential for soft tissue repair and regeneration. *Vasc Cell* 2014;6:10. <http://dx.doi.org/10.1186/2045-824X-6-10>.
22. Shah A. Using amniotic membrane allografts in the treatment of neuropathic foot ulcers. *J Am Podiatr Med Assoc* 2014;104(2):198–202.
23. Forbes J, Fetterolf DE. Dehydrated amniotic membrane allografts for the treatment of chronic wounds: a case series. *J Wound Care* 2012;21(6):290–6.
24. Fetterolf DE, Snyder RJ. Scientific and clinical support for the use of dehydrated amniotic membrane in wound management. *Wounds* 2012;24(10):299–307.
25. Sheikh ES, Sheikh ES, Fetterolf DE. Use of dehydrated human amniotic membrane allografts to promote healing in patients with refractory non healing wounds. *Int Wound J* 2013. <http://dx.doi.org/10.1111/iwj.12035>.
26. Zelen CM, Serena TE, Denozieri G, et al. A prospective randomized comparative parallel study of amniotic membrane wound graft in the management of diabetic foot ulcers. *Int Wound J* 2013;10(5):502–7.
27. Zelen C. An evaluation of dehydrated human amniotic membrane allografts in patients with DFU's. *J Wound Care* 2013;22(7):347–51.
28. Zelen C, Serena T, Fetterolf D. Dehydrated human amnion/chorion membrane allografts in patients with chronic diabetic foot ulcers: a long term follow-up study. *Wound Medicine* 2014;4:1–4.
29. Zelen C, Serena T, Snyder R. A prospective randomized comparative study of weekly versus biweekly application of dehydrated human amnion/chorion membrane allograft in the management of diabetic foot ulcers. *Int Wound J* 2013; 10(5):1–14.
30. Serena TE, Carter MJ, Le LT, et al. A multi-center randomized controlled trial evaluating the use of dehydrated human amnion/chorion membrane allografts and multi-layered compression therapy vs. multi-layer compression therapy alone in the treatment of venous leg ulcers. *Wound Repair Regen*. <http://dx.doi.org/10.1111/wrr.12227>.
31. Zelen CM, Poka A, Andrews J. Prospective, randomized, blinded, comparative study of injectable micronized dehydrated amniotic/chorionic membrane allograft for plantar fasciitis—a feasibility study. *Foot Ankle Int* 2013;34(10):1332–9.
32. Tissue Reference Group. Available at: [www.fda.gov/BiologicsBloodVaccines/Tissue](http://www.fda.gov/BiologicsBloodVaccines/Tissue). Accessed June 25, 2014.
33. Niknejad H, Peirovi H, Jorjani M, et al. Properties of the amniotic membrane for potential use in tissue engineering. *Eur Cell Mater* 2008;15:88–99.
34. Moore Z, Butcher G, Snyder R, et al. AAWC, AWMA, EWMA position paper; managing wounds as a team. *J Wound Care* 2014;23(5 Suppl.):S1–38.
35. Margolis DJ, Kantor J, Berlin JA. Healing of diabetic neuropathic foot ulcers receiving standard treatment. A meta-analysis. *Diabetes Care* 1999;22:692–5.
36. Margolis DJ, Allen-Taylor L, Hoffstad O, et al. The accuracy of venous leg ulcer prognostic models in a wound care system. *Wound Repair Regen* 2004;12(2): 163–8.
37. Perler AD, Nwosu V, Christie D, et al. End-stage osteoarthritis of the great toe/hallux rigidus: a review of the alternatives to arthrodesis: implant versus osteotomies and arthroplasty techniques. *Clin Podiatr Med Surg* 2013;30(3):351–95. <http://dx.doi.org/10.1016/j.cpm.2013.04.011>.

38. Fetterolf DE, Istwan NB, Stanziano GJ. An evaluation of healing metrics associated with commonly used advanced wound care products for the treatment of chronic diabetic foot ulcers. *Manag Care* 2014;23:31–8.
39. Lavery LA, Fulmer J, Shebetka KA, et al. The efficacy and safety of Graftax for the treatment of chronic diabetic foot ulcers: results of a multi-centre, controlled, randomised, blinded, clinical trial. *Int Wound J* 2014;11(5):554–60. <http://dx.doi.org/10.1111/iwj.12329>. Epub 2014 Jul 21.